

A Review of the Special Tests Associated with Shoulder Examination

Part I: The Rotator Cuff Tests

T. Duncan Tennent,* FRCS(Orth), William R. Beach, MD, and John F. Meyers, MD

From Orthopaedic Research of Virginia, Richmond, Virginia

Careful examination of the shoulder is an essential component in forming a diagnosis of problems in this area. A number of tests have been described that are claimed to improve diagnostic accuracy by specifically examining one component of the shoulder complex. Many of these tests are eponymous, and there is confusion about not only how to perform them but also what conclusion to draw from the results. This article attempts to clarify the tests used to examine the rotator cuff by presenting them as described by the original authors with the additional aim of providing a source for those wishing to refresh their knowledge without the need to refer to the original source material.

© 2003 American Orthopaedic Society for Sports Medicine

The shoulder is a complex joint and, by virtue of having a large range of motion, is inherently unstable, relying on the surrounding soft tissue structures for stability. The bony joint consists of the glenoid, acromion, and humeral head, while the soft tissues include the glenoid labrum, the glenohumeral ligaments, and the coracoacromial ligament as well as the muscles of the rotator cuff, the long head of the biceps, and the scapulothoracic muscles. Dysfunction in any one of these components can cause shoulder problems. In many cases, the diagnosis is made from the patient's history of any precipitating event and symptoms described to the physician. The history is often insufficient for diagnosis, requiring a thorough examination to reveal the problem. Because of the number of components of the shoulder joint, special tests have been described that attempt to examine specific elements in isolation. Many of these tests are eponymous and several of the authors have described more than one test, leading to confusion regarding not only the correct way to perform the tests but the correct interpretation of the findings. Misquoting or misinterpreting the tests by subsequent authors has compounded this problem. The first part of this two-part article aims to reduce this confusion by providing descriptions from the original publications for ex-

amination of the rotator cuff. In Part II, to be published in the March/April 2003 issue of this journal, the discussion will center on tests of laxity, stability, and the superior labral, anterior and posterior (SLAP) lesions.

SPECIAL TESTS IN SHOULDER EXAMINATION

Examination of the shoulder should be performed after the examiner has obtained a careful and thorough history. During the examination, the patient should be exposed in such a way that the examiner can see the whole of the upper body, both front and back. If this is not done, the truncal and scapulothoracic muscles and movements cannot be seen. The first step is a careful inspection for scars and asymmetry, followed by palpation. At this stage, the shoulder is put through its active and passive ranges of motion.

There are a large number of special tests described for examination of the shoulder, and it is not feasible to undertake all of them in every examination. They should be used selectively and appropriately to examine the shoulder components of which the clinician is suspicious. This article focuses on examination of the rotator cuff.

ROTATOR CUFF INTEGRITY

Rupture of any of the musculotendinous units associated with the shoulder may be a cause of pain, weakness, instability, or a combination of these symptoms. Testing of rotator cuff integrity should be part of all shoulder exam-

* Address correspondence and reprint requests to T. Duncan Tennent, FRCS(Orth), Orthopaedic Research of Virginia, Suite 207, 7660 Parham Road, Richmond, VA 23294.

No author or related institution has received any financial benefit from creation of this work.

inations. There are two types of integrity tests: first, those that determine whether a movement can be undertaken actively and, second, those that determine whether a passive position can be maintained (the lag signs). Gerber and his associates^{3,4} and Hertel et al.⁹ have described the majority of these signs.

Lift-off Test

Gerber and Krushell⁴ described the lift-off test for examination of an isolated rupture of the subscapularis tendon in 1991 (Fig. 1). They reported: "This test is based on our observation that weakness of internal rotation is most easily demonstrated at the limit of amplitude of contraction of the muscle, namely, when the arm is fully extended and internally rotated. A patient with subscapularis rupture is unable to lift the dorsum of his hand off his back, a finding which we call a 'pathologic lift-off test.'"

In this series, a normal test result was seen in 100 patients who had no shoulder complaints, 27 patients with a full-thickness rotator cuff tear not involving the subscapularis tendon, 17 patients with recurrent anterior dislocation, and 4 patients with recurrent posterior subluxation. In nine of the patients tested who had full-thickness subscapularis tendon tears, eight had tests that revealed abnormalities and one had normal test results.

Greis et al.⁶ undertook an EMG analysis of the lift-off test and confirmed that the subscapularis muscle was maximally active with the hand in the midlumbar position and with resistance applied. The other internal rotator muscles (especially the pectoralis major) demonstrated minimal activity in this position.

Stefko et al.¹⁶ analyzed alternative hand positions for the lift-off test in normal and subscapularis muscle-deficient subjects, as well as the normal subjects after local anesthetic blockade of the muscle. The only position in which all subjects were consistently unable to perform the

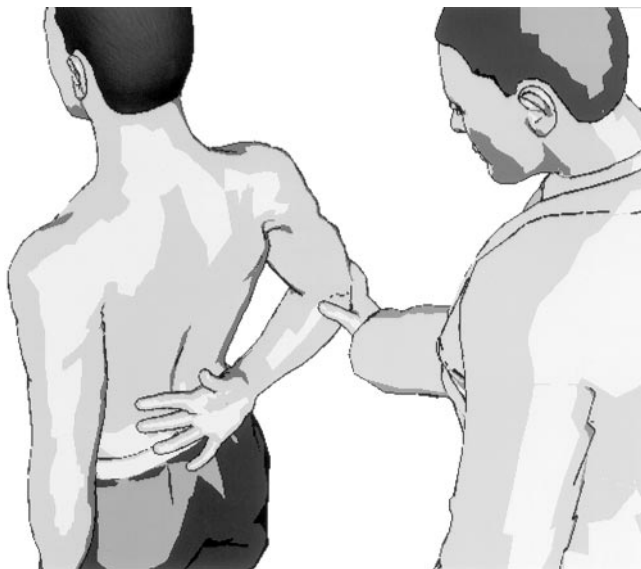

Figure 1. Depiction of the lift-off test.

lift-off test was in maximal internal rotation, with the hand held up against the inferior aspect of the scapula.

Lift-off Test (Lag Sign)

In 1996, Gerber et al.³ described the lift-off test for subscapularis muscle rupture. This newest report showed that "The test is performed by bringing the arm passively behind the body into maximal internal rotation. The result of this test is considered normal if the patient maintains maximum internal rotation after the examiner releases the patient's hand." In this series, the test was positive for 13 of 16 cases. This test is in fact a lag sign rather than an active test, although it was given the same name by Gerber, who had reported on this muscle earlier.

Belly Press Test

Gerber et al.³ described this test in the same study as the lift-off test for patients in whom there was decreased internal rotation (Fig. 2.). They reported: "In this test the patient presses the abdomen with the flat of the hand and attempts to keep the arm in maximal internal rotation. If active internal rotation is strong, the elbow does not drop backward, meaning that it remains in front of the trunk. If the strength of subscapularis is impaired, maximum internal rotation cannot be maintained, the patient feels weakness, and the elbow drops back behind the trunk. The patient exerts pressure on the abdomen by extending

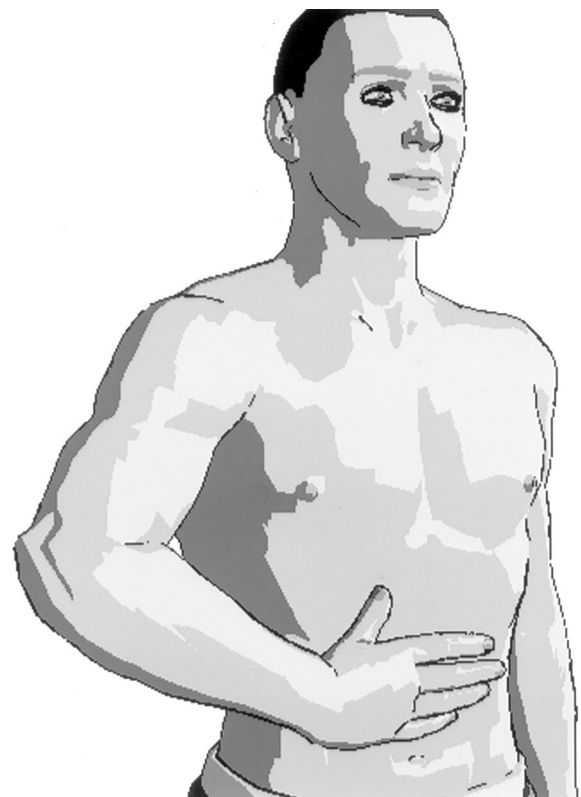


Figure 2. Depiction of the belly press test.

the shoulder rather than by internally rotating it.” In this series, all eight patients had a positive test.

LAG SIGNS

As previously mentioned, Gerber et al.³ described a lag sign for rupture of the subscapularis tendon in 1996. Hertel et al.⁹ described all of the following tests in a prospective assessment of 100 patients; the diagnosis was confirmed at arthroscopy.

External Rotation Lag Sign

“The patient is seated on an examination couch with his or her back to the physician. The elbow is passively flexed to 90°, and the shoulder is held at 20° elevation (in the scapular plane) and near maximum external rotation (i.e., maximum external rotation minus 5° to avoid elastic recoil in the shoulder) by the physician. The patient is then asked to actively maintain the position of external rotation as the physician releases the wrist while maintaining support of the limb at the elbow. The sign is positive when a lag, or angular drop, occurs. The magnitude of the lag is recorded to the nearest 5°. For small ruptures the movement may be subtle with a magnitude as little as 5°. With practice this movement can be clearly appreciated, particularly when compared with the (normal) contralateral side. Testing and interpretation are complicated by pathologic changes in the passive range of motion. When the passive range of motion is reduced because of capsular contracture or increased because of subscapularis rupture, for instance, false-negative and false-positive results, respectively, must be expected. The ERLS [external rotation lag sign] is designed to test the integrity of the supraspinatus and infraspinatus tendons.” This test is demonstrated in Figure 3.

Drop Sign

“The patient is seated on an examination couch with his or her back to the physician, who holds the affected arm at 90° of elevation (in the scapular plane) and at almost full external rotation, with the elbow flexed at 90°. In this position the maintenance of the position of external rotation of the shoulder is a function mainly of the infraspinatus. The patient is asked to actively maintain this position as the physician releases the wrist while supporting the elbow. The sign is positive if a lag or ‘drop’ occurs. The magnitude of the lag is recorded to the nearest 5°. Limitations in testing and interpretation are the same as for the IRLS [internal rotation lag sign]. The drop sign is designed to assess the function of infraspinatus.” This test is demonstrated in Figure 4.

Internal Rotation Lag Sign

“The patient is seated on an examination couch with his or her back to the physician. The affected arm is held by the physician at almost maximal internal rotation. The elbow is flexed to 90°, and the shoulder is held at 20° elevation

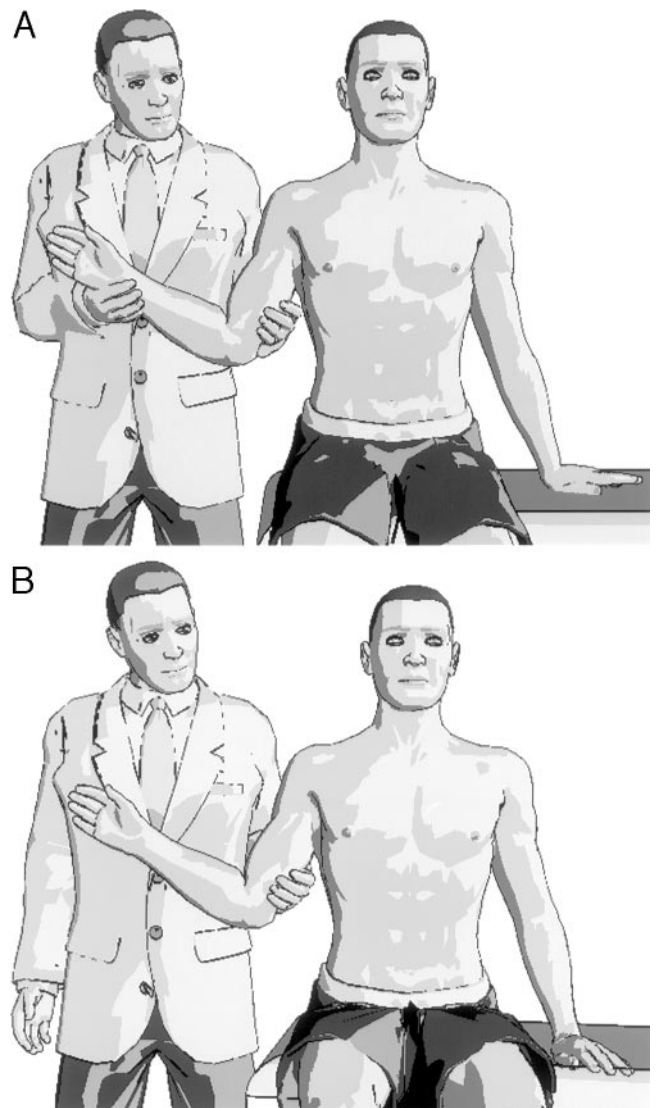


Figure 3. Depiction of the external rotation lag sign. A, start position; B, release.

and 20° extension. The dorsum of the hand is passively lifted away from the lumbar region until almost full internal rotation is reached. The patient is then asked to actively maintain this position as the physician releases the wrist while maintaining support at the elbow. The sign is positive when a lag occurs. The magnitude of the lag is recorded to the nearest 5°. An obvious drop of the hand occurs with large tears. A slight lag indicates a partial tear of the cranial part of the subscapularis tendon. Limitations applied to the testing and interpretation of the ERLS [external rotation lag sign] also apply in testing for the IRLS [internal rotation lag sign]. The IRLS is designed to test for the integrity of the subscapularis tendon.”

Hertel et al.⁹ concluded that for posterosuperior rotator cuff tears the Jobe sign (explained later) was more sensitive than the external rotation lag sign and the external

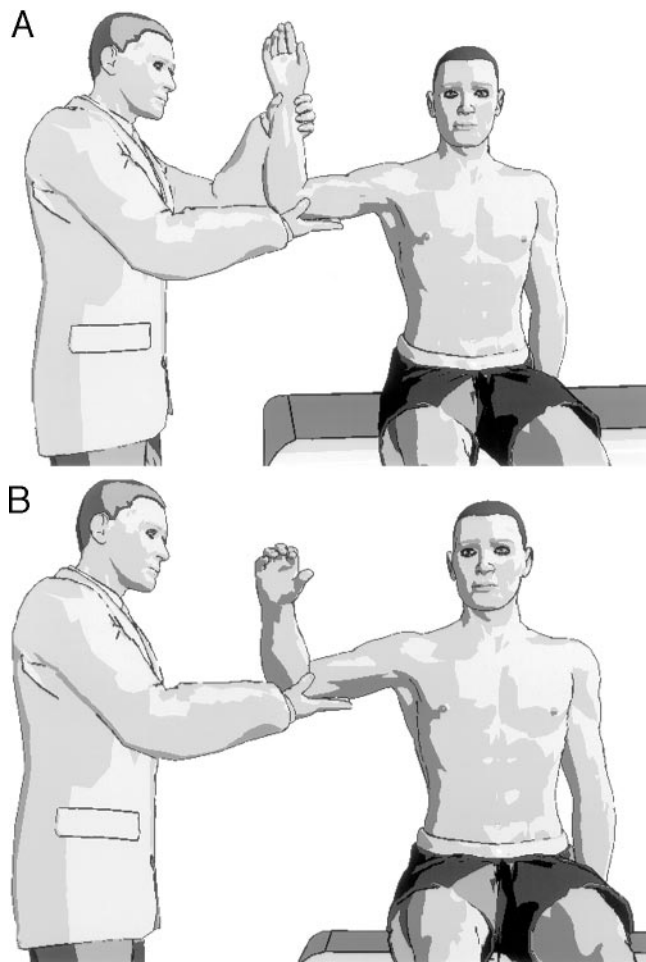


Figure 4. Depiction of the drop sign. A, start position; B, release.

rotation lag sign was more sensitive than the drop sign. There was no difference in accuracy of the Jobe sign and external rotation lag sign and both were more accurate than the drop sign. Positive predictive value for the Jobe sign was 84%, and the negative predictive value was 58%. The external rotation lag sign and drop sign both had 100% positive predictive values and 56% and 32% negative predictive values, respectively.

For subscapularis muscle tears, the internal rotation lag sign was more sensitive and more accurate than the lift-off sign, but both were equally specific. The lift-off sign had a positive predictive value of 100% and a negative predictive value of 69%. The internal rotation lag sign had a positive predictive value of 97% and a negative predictive value of 69%.

Hertel et al.⁹ also examined the relationship between the magnitude of the lag signs and the extent of rotator cuff tears. If the cuff was intact, no lag was seen with the external rotation lag sign, the drop sign, or the internal rotation lag sign. A lag of 5° to 10° was seen in 16 of 17 patients with an isolated supraspinatus tendon tear. All patients with combined supraspinatus and infraspinatus tendon ruptures had a lag of 10° to 15°. Four of the five

patients with partial ruptures of the subscapularis tendon demonstrated lag signs of 5°, and all of those with complete ruptures had lag signs of 5° to 10°.

IMPINGEMENT TESTS

These tests are intended either to reproduce symptoms or produce pain, which is indicative of focal abnormalities.

Neer's Impingement Sign and Impingement Test

Neer¹⁵ first made mention of an impingement test in 1972 when he described one of the diagnostic features as being "pain at the anterior edge of the acromion on forced elevation." A fuller description was given in 1983¹⁴: "The impingement sign is elicited with the patient seated and the examiner standing. . . . Scapular rotation is prevented by one hand as the other raises the arm in forced forward elevation (somewhere between flexion and abduction), causing the greater tuberosity to impinge against the acromion. This manoeuvre causes pain in the patients with impingement lesions of all stages. It also causes pain in patients with many other shoulder conditions, including stiffness (partial frozen shoulder), instability (e.g., an anterior subluxation), arthritis, calcium deposits, and bone lesions. However, pain on this manoeuvre due to impingement can usually be completely eliminated or markedly reduced by the injection of 10 ml of 1.0% xylocaine beneath the anterior acromion. Pain due to other causes, with the exception perhaps of some calcium deposits, is not relieved. This is the 'impingement test' which has been helpful in distinguishing impingement lesions from other causes of chronic shoulder pain." This test is demonstrated in Figure 5.

An anatomic study revealed soft tissue contact with the medial aspect of the acromion in all specimens when the shoulder was in the "Neer position."¹⁷ In 3 of 5 specimens,

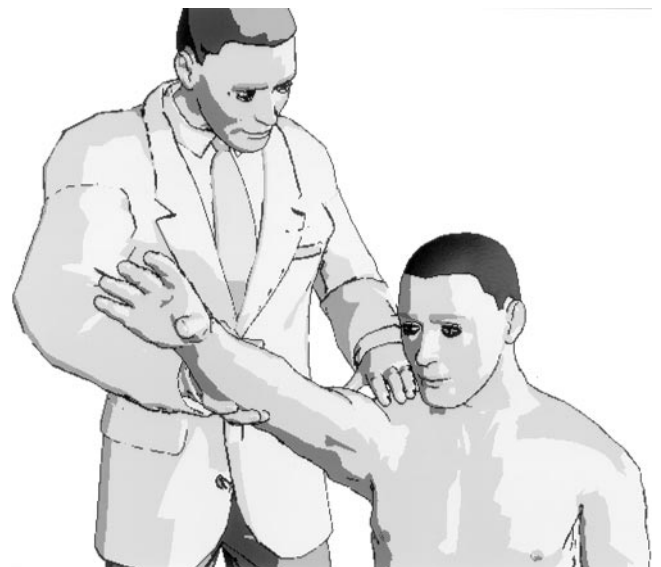

Figure 5. Neer's impingement test.

the greater tuberosity impinged on the lateral acromion, and in the same number the biceps tendon impinged. In all specimens, the undersurface of the cuff contacted either the anterior or superior rim of the glenoid. In no cases did the coracoid impinge. In an arthroscopic study, there was no significant difference in the rate of internal impingement seen arthroscopically for those with and without positive impingement tests (Neer and Hawkins), raising doubt as to its significance.¹³

One analysis revealed a sensitivity for the impingement sign of 75% for bursitis and 88% for cuff abnormalities, with specificities of 48% and 51%, respectively.¹² The positive predictive values were 36% and 40%, and the negative predictive values were 83% and 89%. The test was positive in 25% of Bankart lesions and 46% of SLAP lesions. Of the patients with acromioclavicular joint arthritis, 69% had a positive test result.

Hawkins' Test

Hawkins and Kennedy⁸ described a test in 1980 as an alternative to that described by Neer. They believed, however, that the test was not as reliable as the Neer test: "Another less reliable method of demonstrating this impingement involves forward flexing the humerus to 90° and forcibly internally rotating the shoulder. This maneuver drives the greater tuberosity farther under the coracoacromial ligament similarly reproducing the impingement pain." Figure 6 provides a demonstration of this test.

In an anatomic study, all specimens demonstrated contact between the coracoacromial ligament and either the rotator cuff or the biceps tendon.¹⁷ There was also contact between the articular surface of the cuff and the antero-superior glenoid rim.

One analysis revealed a sensitivity of 92% for bursitis and 88% for cuff abnormalities, with specificities of 44%

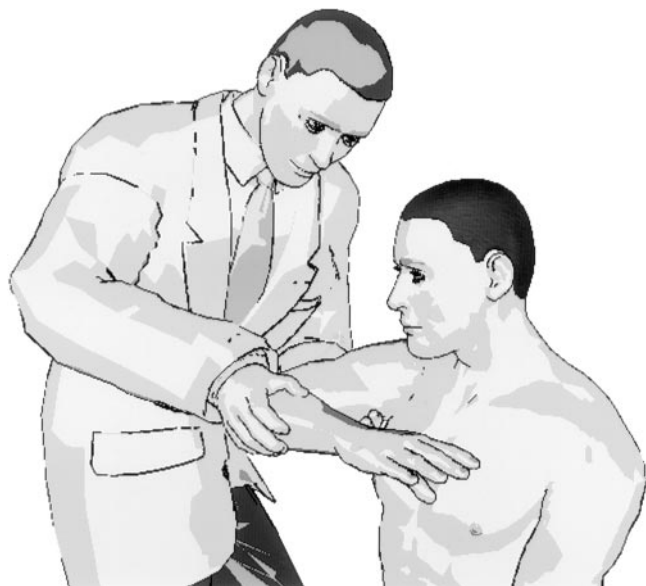

Figure 6. Hawkins' impingement test.

and 43%, respectively.¹² The positive predictive values were 39% and 37%, and the negative predictive values were 93.1% and 90%. The test was positive in 31% of Bankart lesions and 69% of SLAP lesions. Of the patients with acromioclavicular joint arthritis, 94% had a positive test result.

Jobe's Test

Jobe and Jobe¹⁰ described the "supraspinatus test" in 1983. They reported: "The supraspinatus test is performed by first assessing the deltoid with the arm at 90° of abduction and neutral rotation. The shoulder is then internally rotated and angled forward 30°; the thumbs should be pointing toward the floor. Muscle testing against resistance will clearly demonstrate a weakness or insufficiency of the supraspinatus secondary to a tear or pain associated with rotator cuff impingement." Figure 7 is a demonstration of this test.

The citation that is most often quoted for this test is the Jobe and Moynes¹¹ 1982 article. This maneuver was originally described for testing the muscle strength and as a rehabilitation procedure, not as a provocative test. The authors reported that "the subject should be seated with the arms abducted 90°, horizontally flexed 30°, and internally rotated. While in this position, he can raise (concentric contraction) and lower (eccentric contraction) his arms, beginning with small weights and progressing to larger ones."

Yocum's Test

Yocum¹⁹ described a test in 1983 as a way of selectively testing the function of the supraspinatus muscle. He said ". . . [W]hen the patient abducted his arm 90 degrees, brought the arm forward (forward flexion) 30 degrees, and maximally internally rotated the arm (thumb down)." This description appears very similar to that described in Jobe's test.

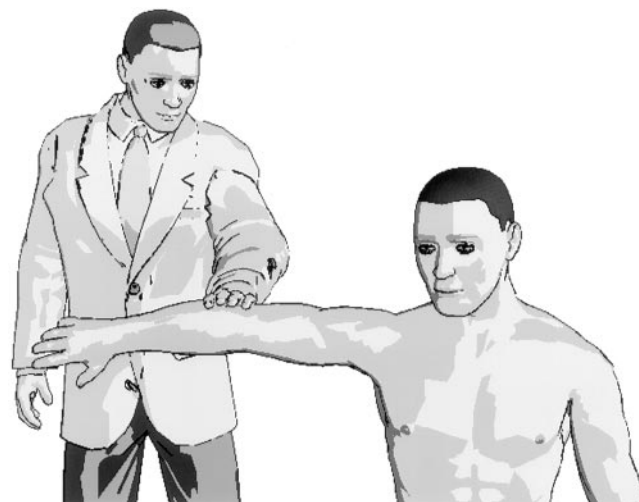


Figure 7. Jobe's supraspinatus muscle test.

Internal Rotation Resistance Stress Test

Zaslav²⁰ described a test for internal rotation resistance stress in 2001 as part of a prospective study of 110 patients to differentiate between intraarticular and outlet impingement syndrome. For inclusion in the study, all patients had to have a positive Neer impingement sign. "The IRRST [internal rotation resistance stress test] is performed in the standing position with the examiner positioned behind the patient. The arm is positioned in 90° of abduction in the coronal plane and approximately 80° of external rotation. A manual isometric muscle test is performed for external rotation and then compared with one for internal rotation in the same position. If a patient with a positive impingement sign has good strength in external rotation in this position and apparent weakness in internal rotation, the IRRST result is considered positive. Because this is a test of relative weakness in a pathologic shoulder, strength is not compared with the contralateral normal arm.

"... [A] positive IRRST in a patient with a positive impingement sign would be predictive of internal (non-outlet) impingement, whereas a negative test (more weakness in external rotation) would suggest classic outlet impingement." Figure 8 provides a demonstration of the internal rotation resistance stress test.

In the study, the specificity was 96% and the sensitivity was 88%. The positive predictive value was 88% and the negative predictive value was 94%. When examining these numbers, it must be noted that the population had all been selected by having a prior positive Neer impingement test and was therefore a population of "impingers" rather than a population with unconfirmed shoulder abnormalities.

Gerber's Subcoracoid Impingement Test

Gerber et al.⁵ described two tests to reproduce entrapment of the rotator cuff between the humeral head and the coracoid process. The most sensitive of the tests was described as "Abduction to 90° combined with medial rotation was restricted and was consistently painful; sometimes it reproduced the radiation to the upper arm and forearm." This position resulted in the smallest coracohumeral distance. The second test, "forward flexion combined with medial rotation," was the most sensitive at detecting impingement produced as a result of iatrogenic or traumatic change in anatomy.

Modified Relocation Test

Hamner et al.⁷ described a variation of Jobe's relocation test (described later) in 2000 to assess "internal impingement." "The modified relocation test was performed at 90°, 110° and 120° of shoulder abduction and in maximal external rotation, the modification being the additional testing positions at 110° and 120°. The test was done with the patient supine and with the affected arm in maximal external rotation and abducted in the coronal plane. During the clinical test, the examiner evaluated for pain, with

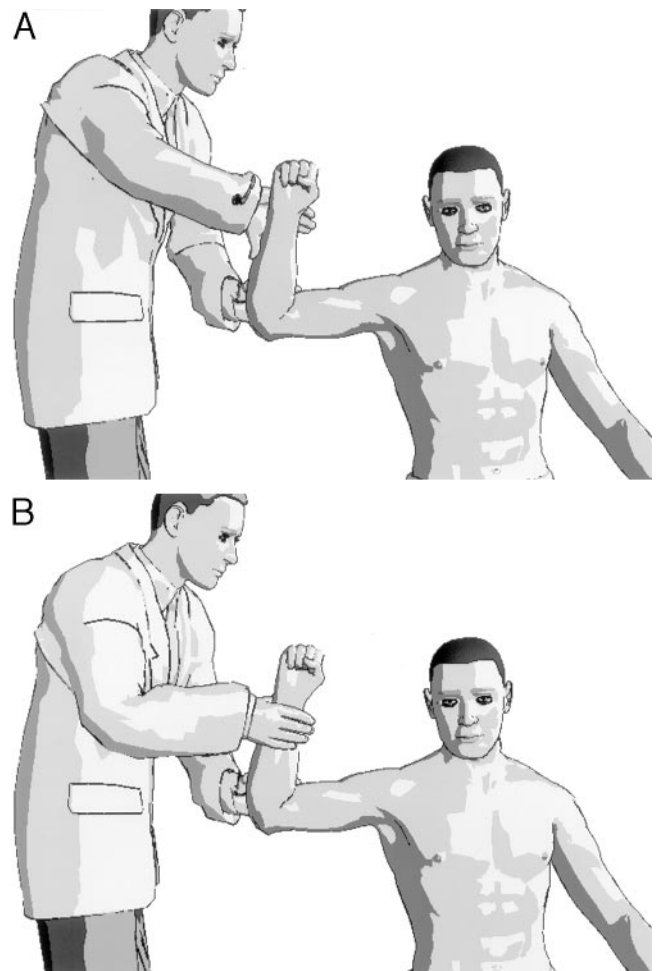


Figure 8. Depiction of the internal rotation resistance stress test. A, external rotation; B, internal rotation.

first an anterior and then a posterior directed force applied to the proximal humerus. A positive test occurred when the patient experienced pain with an anterior force and the pain was relieved with a posterior (relocated) directed force. The location of the pain was recorded."

The test was evaluated arthroscopically in 14 patients. Eleven patients demonstrated fraying of the undersurface of the rotator cuff, and 10 had fraying of the posterosuperior labrum. No attempt was made to analyze the sensitivity or specificity of this test.

Speed's Test

Speed never described the test that bears his name. In 1966 Crenshaw and Kilgore² described the test, citing "personal communication" as the source. "It is performed by having the patient flex his shoulder (elevate it anteriorly) against resistance while the elbow is extended and the forearm supinated. The test is positive when pain is localized to the bicipital groove."

An arthroscopic analysis that included biceps tendon inflammation and SLAP lesions as positive findings pro-

duced a specificity of 14% and a sensitivity of 90%.¹ The positive predictive value was 23% and the negative predictive value was 83%.

Yergason's Sign

The "supination sign" was described by Yergason¹⁸ in 1931 on the basis of a case report. "If the elbow is flexed to 90 degrees, the forearm being pronated; and the examining surgeon holds the patient's wrist so as to resist supination, and then directs that active supination be made against his resistance; pain, very definitely localized in the bicipital groove, indicates a condition of wear and tear of the long head of the biceps, or synovitis of its tendon sheath." Yergason also observed that the sign would be negative in cases of partial or complete rupture of the supraspinatus tendon.

DISCUSSION

The shoulder is a complex structure with two articulating surfaces as well as an articulation between the scapula and the chest wall. The four muscles of the rotator cuff as well as the long head of biceps and deltoid muscle are intimately involved with the joint. The nature of the joint gives rise to a range of problems from instability to arthritis to muscle attrition and rupture. As patients are often unable to describe their problem in such a way as to confirm the diagnosis, clinical examination is essential. Over 30 tests will have been identified in the two parts of this review, and there are many more tests that are used less commonly. Unfortunately, often these tests are of little help in confirming a diagnosis and many, for example, Yergason's sign, were originally described without recourse to evidence-based medicine, but have now become part of the standard orthopaedic criteria. Because of the pedagogical nature of medical teaching, few clinicians return to the descriptions of the original authors, but they rely on demonstration by their tutors. The result of this is that tests are not performed as originally described, and the findings are not interpreted as originally intended.

Examination of the rotator cuff is difficult because abnormalities can produce pain, weakness, or both. For some of the tests, electromyographic analysis has confirmed that the appropriate muscle is being tested; however, in the case of the lift-off test described by Gerber and Krushell,⁴ there is some evidence¹⁶ that it may be unreliable if not performed in a precise manner; unfortunately, the position required for this test (maximal internal rotation) is not achievable for many patients. Other tests, such as the external rotation lag sign³ and the drop sign,³ rely on subtle differences of as little as 5°, resulting in a small margin for error.

The impingement tests are probably the most investigated of all of the shoulder examinations and although they are reasonably sensitive, they are poorly specific.^{8,10,15} Other tests, such as the internal rotation resistance stress test described by Zaslav,²⁰ have not been validated in any other research to date.

One observation that can be made, and indeed was made by some of the earlier authors, is that none of these tests is absolutely diagnostic for any one pathologic entity.

Clearly, it is not appropriate for the clinician to use every test on every patient. This review is intended to produce in one place the original descriptions of a number of these tests with what statistical analysis is available to allow clinicians to decide which tests are worth using, how they should be performed, and what the correct interpretations of the results are.

REFERENCES

- Bennett WF: Specificity of the Speed's test: Arthroscopic technique for evaluating the biceps tendon at the level of the bicipital groove. *Arthroscopy* 14: 789-796, 1998
- Crenshaw AH, Kilgore WE: Surgical treatment of bicipital tenosynovitis. *J Bone Joint Surg* 48A: 1496-1502, 1966
- Gerber C, Hersche O, Farron A: Isolated rupture of the subscapularis tendon. *J Bone Joint Surg* 78A: 1015-1023, 1996
- Gerber C, Krushell RJ: Isolated rupture of the tendon of the subscapularis muscle. Clinical features in 16 cases. *J Bone Joint Surg* 73B: 389-394, 1991
- Gerber C, Terrier F, Ganz R: The role of the coracoid process in the chronic impingement syndrome. *J Bone Joint Surg* 67B: 703-708, 1985
- Greis PE, Kuhn JE, Schultheis J, et al: Validation of the lift-off test and analysis of subscapularis activity during maximal internal rotation. *Am J Sports Med* 24: 589-593, 1996
- Hammer DL, Pink MM, Jobe FW: A modification of the relocation test: Arthroscopic findings associated with a positive test. *J Shoulder Elbow Surg* 9: 263-267, 2000
- Hawkins RJ, Kennedy JC: Impingement syndrome in athletes. *Am J Sports Med* 8: 151-158, 1980
- Hertel R, Ballmer FT, Lombert SM, et al: Lag signs in the diagnosis of rotator cuff rupture. *J Shoulder Elbow Surg* 5: 307-313, 1996
- Jobe FW, Jobe CM: Painful athletic injuries of the shoulder. *Clin Orthop* 173: 117-124, 1983
- Jobe FW, Moynes DR: Delineation of diagnostic criteria and a rehabilitation program for rotator cuff injuries. *Am J Sports Med* 10: 336-339, 1982
- MacDonald PB, Clark P, Sutherland K: An analysis of the diagnostic accuracy of the Hawkins and Neer subacromial impingement signs. *J Shoulder Elbow Surg* 9: 299-301, 2000
- McFarland EG, Hsu CY, Neira C, et al: Internal impingement of the shoulder: A clinical and arthroscopic analysis. *J Shoulder Elbow Surg* 8: 458-460, 1999
- Neer CS II: Impingement lesions. *Clin Orthop* 173: 70-77, 1983
- Neer CS II: Anterior acromioplasty for the chronic impingement syndrome in the shoulder: A preliminary report. *J Bone Joint Surg* 54A: 41-50, 1972
- Stefko JM, Jobe FW, VanderWilde RS, et al: Electromyographic and nerve block analysis of the subscapularis lift-off test. *J Shoulder Elbow Surg* 6: 347-355, 1997
- Valadie AL III, Jobe CM, Pink MM, et al: Anatomy of provocative tests for impingement syndrome of the shoulder. *J Shoulder Elbow Surg* 9: 36-46, 2000
- Yergason RM: Supination sign. *J Bone Joint Surg* 13: 160, 1931
- Yocum LA: Assessing the shoulder. History, physical examination, differential diagnosis, and special tests used. *Clin Sports Med* 2: 281-289, 1983
- Zaslav KR: Internal rotation resistance strength test: A new diagnostic test to differentiate intra-articular pathology from outlet (Neer) impingement syndrome in the shoulder. *J Shoulder Elbow Surg* 10: 23-27, 2001