

A Review of the Special Tests Associated with Shoulder Examination

Part II: Laxity, Instability, and Superior Labral Anterior and Posterior (SLAP) Lesions

T. Duncan Tennent,* FRCS(Orth), William R. Beach, MD, and John F. Meyers, MD

From Orthopaedic Research of Virginia, Richmond, Virginia

This is the second of a two-part article describing the various tests that have been used to examine the shoulder to find and treat problems in that area. Part I of this article (January/February 2003, pages 154–160) focused on tests used to examine rotator cuff abnormalities. This article attempts to clarify the tests of laxity, instability, and the superior labral anterior and posterior (SLAP) lesions by presenting them as described by the original authors, with the additional aim of providing a source for those wishing to refresh their knowledge without the need to refer to the original source material.

© 2003 American Orthopaedic Society for Sports Medicine

As described in Part I of this two-part article, the shoulder is a complex joint; its large range of motion makes it inherently unstable and it must rely on the surrounding soft tissue structures for stability. Shoulder problems arise when there is dysfunction in any one of these components. Diagnosis of the problem often depends to a large extent on thorough history-taking and analysis of symptoms. However, the history is often unsatisfactory, making physical examination necessary to help determine the cause of the problem. Just as there are special tests used to examine the rotator cuff, there are also special tests used to examine laxity, instability, and superior labral anterior and posterior (SLAP) lesions. Part II of this two-part article describes the special tests used for examination of the shoulder to determine laxity, instability, and SLAP lesions.

LAXITY TESTS

Increased joint laxity has been associated with instability, and a number of researchers have described techniques to reproduce this laxity in a reliable way. All of these tests indicate joint laxity only and should not be interpreted as indicating instability.

* Address correspondence and reprint requests to T. Duncan Tennent, FRCS(Orth), Orthopaedic Research of Virginia, Suite 207, 7660 Parham Road, Richmond, VA 23294.

No author or related institution has received any financial benefit from creation of this work.

Sulcus Sign

The sulcus sign has never been truly described; however, the earliest reference to this test (and the one used by most articles) is that by Neer and Foster.¹³ Even though the test is not described, there is a photograph of a patient in whom “inferior subluxation is produced by downward traction on the arm.” If a depression is observed between the lateral edge of the acromion and the humeral head on gentle downward traction of the humerus, the sulcus sign can be said to be positive. A clearer description with quantification was provided by Silliman and Hawkins¹⁶ (to be described here later).

TRANSLATION TESTS

The Anterior Drawer Test

As described by Gerber and Ganz³ in 1984, “The test is performed with the patient supine. It should not be performed with the patient standing or sitting; in these positions we have not been able to reproduce it reliably. The examiner stands facing the affected shoulder. Assuming the left shoulder is being tested, he fixes the patient’s left hand in his own right axilla by adducting his own humerus. The patient should not grasp the surgeon’s axilla but should be completely relaxed. To be sure that relaxation is complete, the examining surgeon gently taps the patient’s elbow.

“The affected shoulder is held in 80 degrees to 120

degrees of abduction, 0 degrees to 20 degrees of forward flexion, and 0 degrees to 30 degrees of lateral rotation; this position should be quite comfortable. The examiner holds the patient's scapula with his left hand, pressing the scapular spine forward with his index and middle fingers; his thumb exerts counter-pressure on the coracoid process. The scapula is now held firmly in the examiner's left hand. With his right hand, he grasps the patient's relaxed upper arm in its resting position and draws it anteriorly with a force comparable to that used at the knee in Lachman's test. The relative movement between the fixed scapula and the movable humerus can easily be appreciated and can be graded as with knee instability."

The Posterior Drawer Test

Gerber and Ganz³ also described this test: "The patient must be supine. The examiner stands level with the affected shoulder. Assuming the left shoulder is being tested, he grasps the patient's proximal forearm with his left hand, flexes the elbow to about 120 degrees, and positions the shoulder into 80 degrees to 120 degrees of abduction and 20 degrees to 30 degrees of forward flexion. The examiner holds the scapula with his right hand, with his index and middle fingers on the scapular spine; his thumb lies immediately lateral to the coracoid process, so that its ulnar aspect remains in contact with the coracoid while performing the test. With his left hand, the examiner slightly rotates the upper arm medially and flexes it to about 60 degrees or 80 degrees; during this manoeuvre, the thumb of the examiner's right hand subluxates the humeral head posteriorly. This posterior displacement can be appreciated as the thumb slides along the lateral aspect of the coracoid process toward the glenoid, and the humeral head abuts against the ring finger of the examiner's right hand. This manoeuvre is painfree but often associated with a slight to moderate degree of apprehension, enabling the patient to identify the position of instability with certainty."

An analysis of the interobserver reliability of the sulcus sign and the laxity tests using Altchek's grading system showed that overall reproducibility was 47% with a kappa value of less than 0.5.¹⁰ The intraobserver reproducibility was only 47%. Most of this discrepancy was with grades 0 and 1. When these grades were combined, the intraobserver reproducibility increased to 73%.

Load and Shift Test

The load and shift test was described by Silliman and Hawkins¹⁶ in 1993. "The patient should be seated for this part of the examination. The examiner should be behind the patient on the side to be examined. The examiner places the hand over the shoulder and scapula to steady the limb girdle and then, with the opposite hand, grasps the humeral head. As the head is 'loaded', both anterior and posterior stresses are applied and the amount of translation is noted. Next, the elbow is grasped and inferior traction is applied. The area adjacent to the acromion is observed, and dimpling of the skin may indicate a 'sul-

cus sign'. . . if present, the 'sulcus sign' should be reported in centimeters (i.e., the number of centimeters the humeral head is displaced from the inferior surface of the acromion).

"Glenohumeral translation is assessed with the patient supine. Here the arm is grasped in a position of approximately 20° abduction and forward flexion in neutral rotation. The humeral head is loaded and then posterior and anterior stresses are applied. Similarly, inferior stress is applied again noting the 'sulcus sign'."

Faber et al.¹ described an alternative version of the load and shift test as part of a comparison of the effects of anesthesia on the results of the test in 1999. "In this test, the humeral head was loaded in such a way as to center it congruently within the glenoid fossa. The humeral head was then maximally stressed or shifted anteriorly and posteriorly so that movement of the humeral head relative to the glenoid face and the glenoid rim could be assessed. The humeral head was stressed with enough force to achieve translation to its end point. Each shoulder was examined with the patient in the supine position and the arm in approximately 20° of abduction, 20° of forward flexion, and neutral rotation. Inferior translation was evaluated by the application of an axial load with the patient's arm resting comfortably by the side."

From the analysis of the effects of anesthesia, the authors concluded that 92% of patients had a higher grade of anterior translation during examination under anesthesia than when awake for both affected and unaffected shoulders. However, this did not imply a pathologic condition and reinforced the observation that both shoulders should be examined on all occasions.

INSTABILITY TESTS

Apprehension Test

Described by Rowe and Zarins¹⁵ in 1981, "This test can be performed when the patient is either in a standing or a supine position. As the shoulder is moved passively into maximum external rotation in abduction and forward pressure is applied to the posterior aspect of the humeral head, the patient suddenly becomes apprehensive and complains of pain in the shoulder." This test is depicted in Figure 1. In Rowe's series, all 60 patients had a positive apprehension test.

Jobe's Apprehension-Relocation Test

This combination test was described by Jobe and Kvitne⁶ in 1989. "These tests are performed with the patient supine and the arm in abduction and external rotation. During the Apprehension Test, the examiner pushes anteriorly on the posterior aspect of the humeral head. This maneuver will produce apprehension sometimes coupled with pain in patients with recurrent dislocations. Patients with anterior subluxation will experience pain but not apprehension with this test, and patients with normal shoulders will be asymptomatic. The Relocation Test is then performed by administering a posteriorly directed

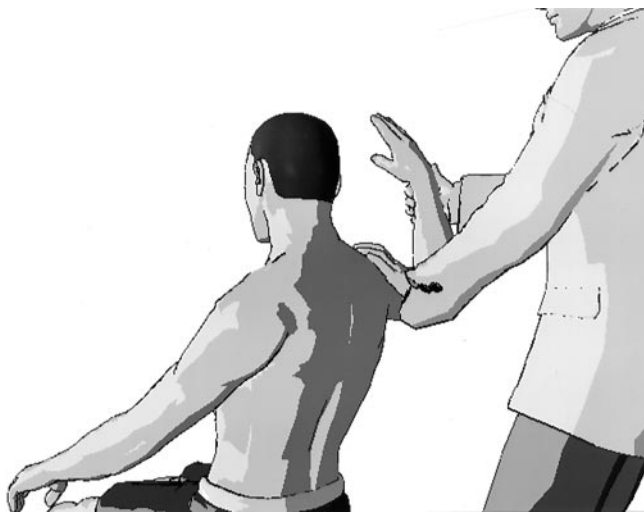


Figure 1. Depiction of Rowe's apprehension test.

force on the humeral head. Patients with primary impingement will have no change in their pain, whereas patients with instability (subluxation) and secondary impingement will have pain relief and will tolerate maximal external rotation with the humeral head maintained in a reduced position."

Evaluation of the test in 1993 concluded that it was common to have pain in the position of 90° of abduction and 90° of external rotation from a variety of disorders and that this will be diminished by a posteriorly directed force.¹⁸ The test became more accurate when apprehension was used as the diagnostic criterion. Sensitivity was 68%; specificity, 100%; positive predictive value, 100%; negative predictive value, 78%; and accuracy, 85% for the relocation test when apprehension was the determinant of a positive result.

Fowler's Sign, the Release Test, and the Augmentation Test

Silliman and Hawkins¹⁶ described the diminution of apprehension with the posteriorly directed force in Jobe's relocation test as "Fowler's sign." They further described the release test: "If the arm is suddenly released when stressed in external rotation abduction the patient has a dramatic increase in pain." They also described the augmentation test: "Similarly, one can augment the pain with external rotation and abduction by pulling forward on the back of the arm."

Anterior Release Test

Gross and Distefano⁴ described the anterior release test in 1997 to identify occult instability. "The anterior release test is performed with the patient in the supine position, with the affected shoulder over the edge of the examining table. The patient's arm is abducted 90° while the examiner places a posteriorly directed force on the patient's humeral head with his hand. The posterior force is main-

tained while the arm is brought into the extreme of external rotation. The humeral head is then released. The result is considered positive if the patient experiences a sudden pain, a distinct increase in pain, or when the patient states that his or her symptoms have been reproduced." This test is depicted in Figure 2. In this series of 82 patients, the sensitivity was 92%, specificity was 89%, positive predictive value was 87%, and the negative predictive value was 93%.

In the article by Gross and Distefano⁴ the observation was made that to fulfil the criteria of Rowe and Zarins¹⁵ for a positive test result, the patient had to experience both apprehension *and* pain, and that the statement by Jobe and Jobe⁵ was that pain alone was suggestive of rotator cuff abnormalities, while pain *and* apprehension suggested instability.

SLAP TESTS

Snyder et al.¹⁷ first classified the SLAP lesion in 1990 in conjunction with the first tests for clinical diagnosis. Since

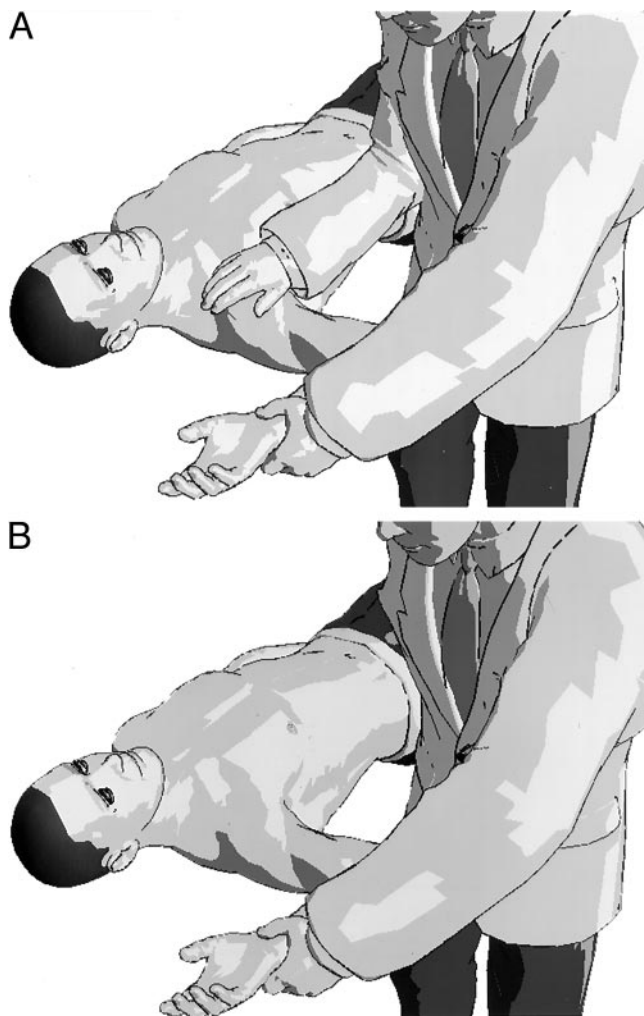


Figure 2. The anterior release test showing the hand on the humeral head creating a posterior-directed force (A) and the hand off the humeral head releasing it (B).

then, there have been a number of alternative tests described to determine this lesion.

Snyder's Biceps Tension Test and Compression-Rotation Test

As stated by Snyder et al.,¹⁷ "On physical examination, the most useful diagnostic tests were the biceps tension test (resisted shoulder flexion with the elbow extended and forearm supinated) and joint compression-rotation test. The compression-rotation test is performed with the patient supine, the shoulder abducted 90° and the elbow flexed at 90°. A compression force is applied to the humerus, which is then rotated, in an attempt to trap the torn labrum. Labral tears may be felt to catch and snap during the test, as meniscal tears do with MacMurray's test." Figure 3 shows the compression-rotation test. No observation was made as to the accuracy of these tests; however, Field and Savoie² observed that the biceps tension test was positive in 20 consecutive patients with a diagnosis of SLAP lesion.

Anterior Slide Test

Kibler⁷ described this test in 1995. "The patient is examined either standing or sitting, with their hands on the hips with thumbs pointing posteriorly. One of the examiner's hands is placed across the top of the shoulder from the posterior direction, with the last segment of the index finger extending over the anterior aspect of the acromion at the glenohumeral joint. The examiner's other hand is placed behind the elbow and a forward and slightly superiorly directed force is applied to the elbow and upper arm. The patient is asked to push back against this force. Pain localized to the front of the shoulder under the examiner's hand, and/or a pop or click in the same area, was considered to be a positive test. This test is also positive if the athlete reports a subjective feeling that this testing maneuver reproduces the symptoms that occur during overhead activity." This test is depicted in Figure 4. The results showed a sensitivity of 78.4% and a specificity of 91.5%. The authors commented that the test was useful as

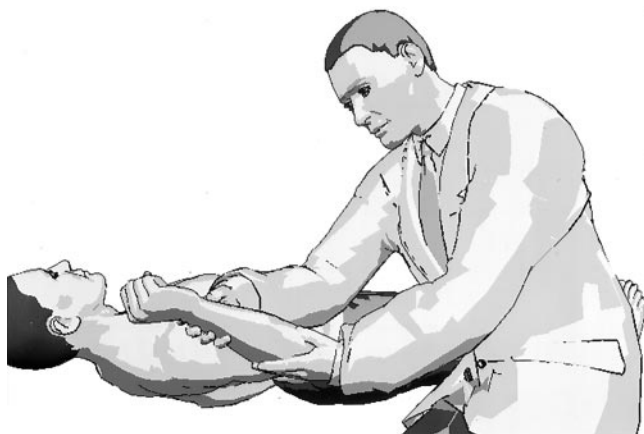

Figure 3. The compression-rotation test.

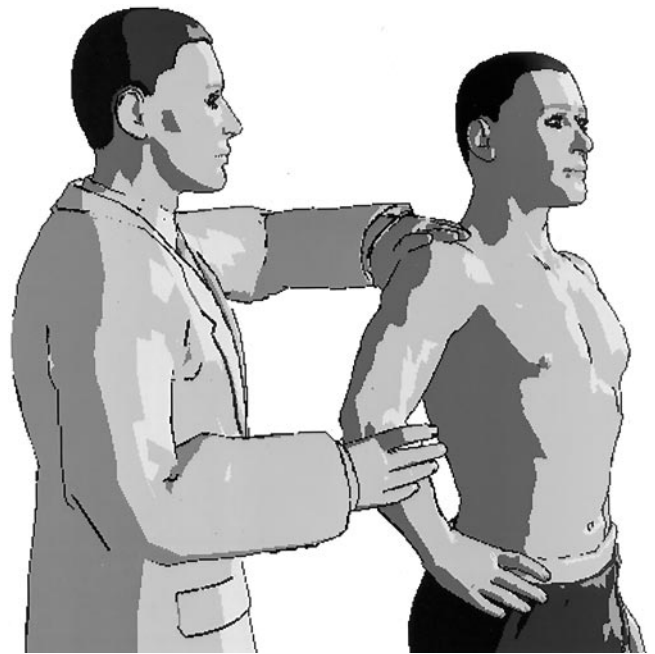


Figure 4. The anterior slide test.

an aid to diagnosis, but was not in itself sufficient to be relied on completely.

The Crank Test

Liu et al.¹¹ described the crank test in 1996: "The crank test is performed with the patient in the upright position with the arm elevated to 160° in the scapular plane. Joint load is applied along the axis of the humerus with one hand while the other performs humeral rotation. A positive test is determined either by 1) pain during the maneuver (usually during external rotation) with or without a click or 2) reproduction of the symptoms, usually pain or catching felt by the patient during athletic or work activities. This test should be repeated in the supine position, where the patient is more relaxed. Frequently, a positive crank test in the upright position will also be positive in the supine position.

"Tricks in performing this test are to make sure elevation is kept as extreme as possible (not at 90° for the apprehension or relocation test), and axial load is applied followed by stress relocation." Figure 5 is a depiction of the crank test.

This description was produced after a study of 62 patients in whom the test was positive in 31 and the diagnosis was confirmed at arthroscopy. The sensitivity was 91% and the specificity was 93%. The positive predictive value was 94% and the negative predictive value was 90%.

O'Brien's Active Compression Test

O'Brien et al.¹⁴ described this test in 1998 to distinguish between superior labral and acromioclavicular abnormalities. The test is depicted in Figure 6. "This test was

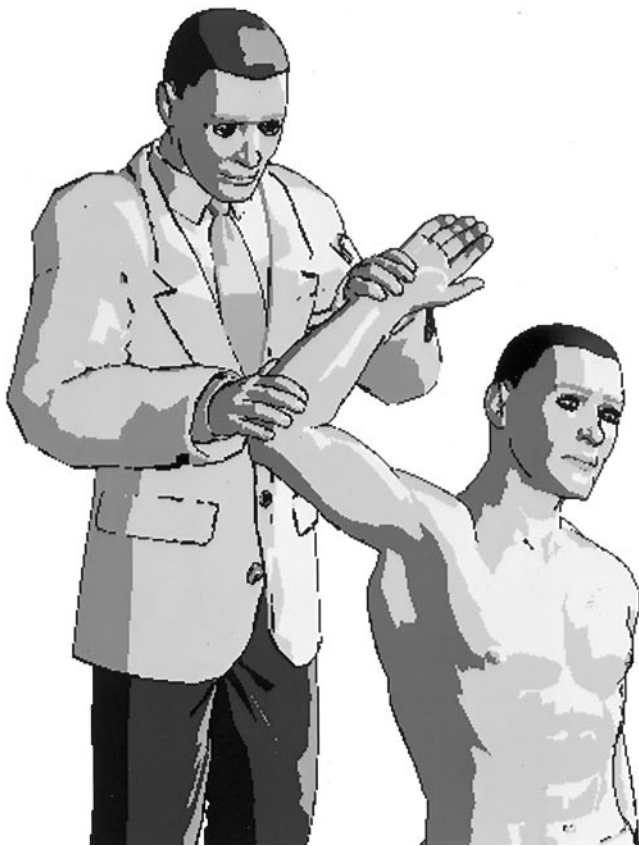


Figure 5. The crank test.

conducted with the physician standing behind the patient. The patient was asked to forward flex the affected arm 90° with the elbow in full extension. The patient then adducted the arm 10° to 15° medial to the sagittal plane of the body. The arm was internally rotated so that the thumb pointed downward. The examiner then applied a uniform downward force to the arm. With the arm in the same position, the palm was then fully supinated and the maneuver was repeated. The test was considered positive if pain was elicited with the first maneuver and was reduced or eliminated with the second maneuver. Pain localized to the acromioclavicular joint or on top of the shoulder was diagnostic of acromioclavicular joint abnormality. Pain or painful clicking described as within the glenohumeral joint itself was indicative of labral abnormality.” The results in their series of over 300 patients were a sensitivity of 100%, a specificity of 99%, a positive predictive value of 95%, and a negative predictive value of 100% for labral abnormalities. For the acromioclavicular joint, the sensitivity was 100%, the specificity was 97%, the positive predictive value was 89%, and the negative predictive value was 89%.

Pain Provocation Test

Mimori et al.¹² described another SLAP provocative test in 1999 (depicted in Fig. 7.). “The new pain provocation test was performed with the patient in the sitting position.

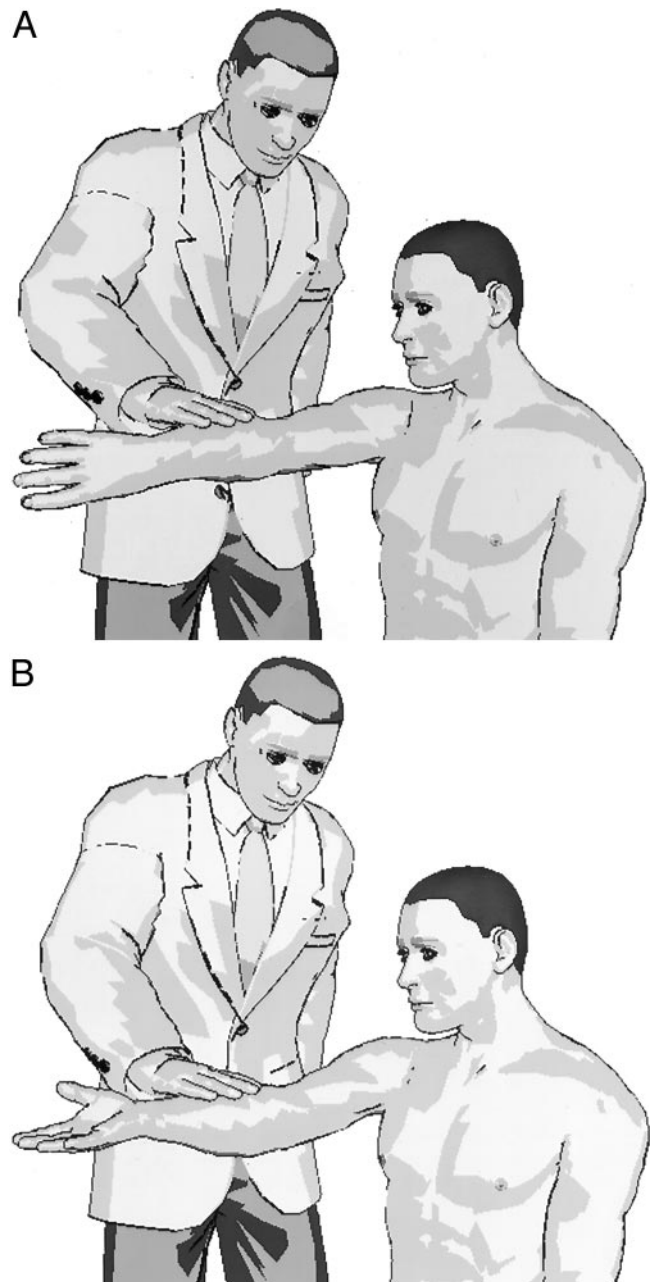


Figure 6. The active compression test. A, thumb down; B, palm up.

During testing, the abduction angle of the upper arm was maintained at 90° to 100° , and the shoulder was rotated externally by the examiner. This maneuver is similar to the anterior apprehension test. The new pain provocation test was performed with the forearm in two different positions: maximum pronation and maximum supination.

“We evaluated the severity of provoked pain based on the subjective rating by the patients themselves when the shoulder was rotated externally with the forearm in the two positions. Patients were asked ‘in which position of the forearm do you feel more severe pain, in pronation or

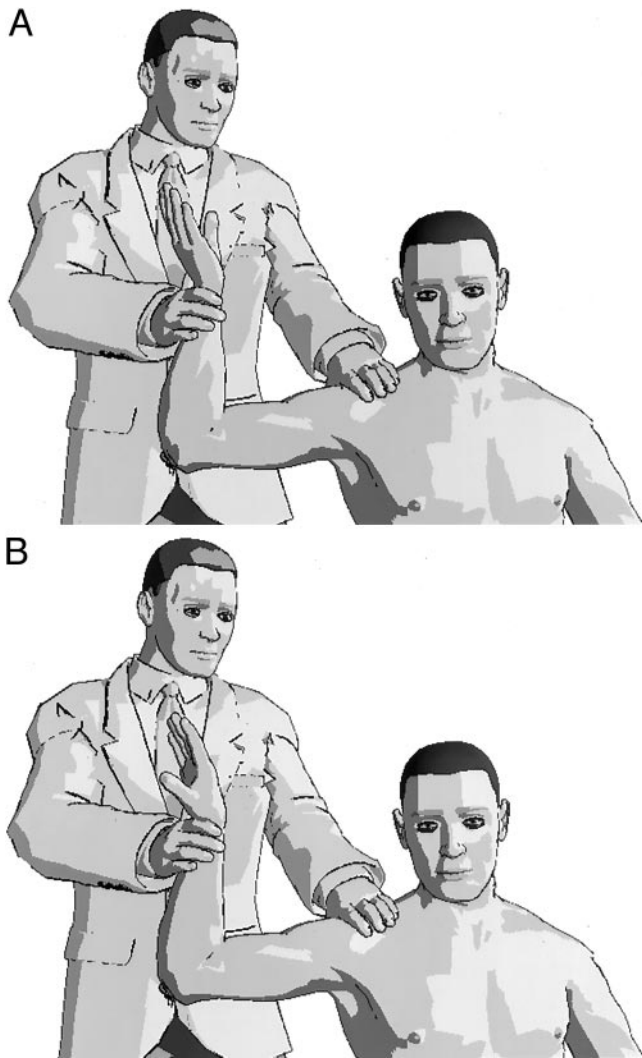


Figure 7. The pain provocation test with the shoulder in supination (A) and pronation (B).

in supination? When the patient was not clearly aware of a difference in the severity of pain, we considered the severity of provoked pain the same for both positions.

“We defined the new pain provocation test as positive for a superior labral tear when pain was provoked only when the forearm was in the pronated position or when pain was more severe in this position than with the forearm supinated.”

This test was analyzed in 32 patients and compared with magnetic resonance arthrography and arthroscopy as well as the crank test. The conclusion was that when magnetic resonance arthrography was used as the standard, the new test was 100% sensitive and 90% specific, with an accuracy of 97%. Of the 15 patients undergoing arthroscopy, 11 who had positive test results also had a SLAP lesion, and 4 who had negative results did not have a SLAP lesion. The crank test in this study was 83% sensitive and 100% specific with an accuracy of 87%. The comment made, however, was that for the crank test to be

positive, a click had to be elicited, which is not the test as described by the authors (see previous discussion).

Biceps Load Test

In 1999, Kim et al.⁹ described this test for the evaluation of SLAP lesions in patients with recurrent anterior dislocations. “This test is performed with the patient in the supine position. The examiner sits adjacent to the patient on the same side as the affected shoulder and gently grasps the patient’s wrist and elbow. The arm to be examined is abducted at 90°, with the forearm in the supinated position. The patient is allowed to relax and an anterior apprehension test is performed. When the patient becomes apprehensive during the external rotation of the shoulder, external rotation is stopped. The patient is then asked to flex the elbow while the examiner resists the flexion with one hand and asks how the apprehension has changed, if at all. If the apprehension is lessened, or if the patient feels more comfortable than before the test, the test is negative for a SLAP lesion. If the apprehension has not changed, or if the shoulder becomes more painful, the test is positive. The test is repeated and the patient is instructed not to pull the whole upper extremity but to bend the elbow against the examiner’s resistance. The examiner should be sitting adjacent to the shoulder to be examined at the same height as the patient, and he or she should also face the patient at a right angle. The direction of the examiner’s resistance should be on the same plane as the patient’s arm so as not to change the degree of abduction and rotation of the shoulder. The forearm should be kept in the supinated position during the test.” This test is depicted in Figure 8.

This test was assessed in 75 patients with a reported sensitivity of 91% and a specificity of 97%. The positive predictive value was 83% and the negative predictive value was 98%.

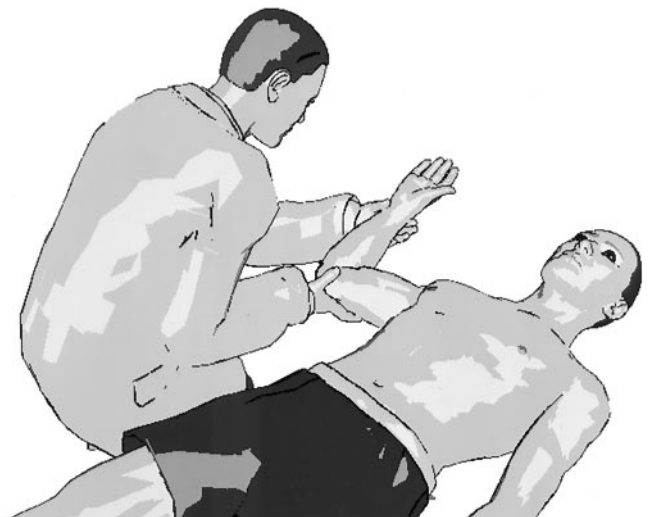

Figure 8. The biceps load test.

Biceps Load Test II

Kim et al.⁸ described a second biceps load test in 2001 for the assessment of SLAP lesions in shoulders without recurrent dislocation. "The test is conducted with the patient in the supine position. The examiner sits adjacent to the patient on the same side as the shoulder and grasps the patient's wrist and elbow gently. The arm to be examined is elevated to 120° and externally rotated to its maximal point, with the elbow in the [sic] 90° flexion and the forearm in the supinated position. The patient is asked to flex the elbow while resisting the elbow flexion by the examiner. The test is considered positive if the patient complains of pain during the resisted elbow flexion and also considered positive if the patient complains of more pain from the resisted elbow flexion regardless of the degree of pain before the elbow flexion maneuver. The test is negative if pain is not elicited by the resisted elbow flexion or if the preexisting pain during the elevation and external rotation of the arm is unchanged or diminished by the resisted elbow flexion."

In the 2001 report, 127 shoulders were evaluated arthroscopically. There were 38 positive tests. The sensitivity was 90%, the specificity was 97%, the positive predictive value was 92%, and the negative predictive value was 96%.

DISCUSSION

A range of tests has recently been described for the SLAP lesion. In contrast to the tests used to detect abnormalities of the rotator cuff, described in Part I of these articles, these tests use statistics to support their diagnostic power and the original authors' analyses all appear to produce excellent sensitivity and specificity. Unfortunately, very few of these new tests have undergone independent analysis of their efficacy. Several of the tests are very similar in appearance and there has been no anatomic study performed to assess the effect of the tests on the biceps/labral complex.

One observation, which may be reasonably made, is that none of these tests is absolutely diagnostic for any one pathologic entity. This implies that we should not rely

blindly on the clinical examination but use it as a part of the diagnostic procedure, in conjunction with the history.

It must be remembered, as stated at the end of Part I, that it is not appropriate for the clinician to use every test on every patient. The purpose of this series of articles was to provide the original descriptions of a number of tests along with statistical analysis, if available, to allow clinicians to decide which tests are worth using, how they should be performed, and how to interpret the results.

REFERENCES

1. Faber KJ, Homa K, Hawkins RJ: Translation of the glenohumeral joint in patients with anterior instability: Awake examination versus examination with the patient under anesthesia. *J Shoulder Elbow Surg* 8: 320-323, 1999
2. Field LD, Savoie FH III: Arthroscopic suture repair of superior labral detachment lesions of the shoulder. *Am J Sports Med* 21: 783-790, 1993
3. Gerber C, Ganz R: Clinical assessment of instability of the shoulder. With special reference to anterior and posterior drawer tests. *J Bone Joint Surg* 66B: 551-556, 1984
4. Gross ML, Distefano MC: Anterior release test. A new test for occult shoulder instability. *Clin Orthop* 339: 105-108, 1997
5. Jobe FW, Jobe CM: Painful athletic injuries of the shoulder. *Clin Orthop* 173: 117-124, 1989
6. Jobe FW, Kvitne RS: Shoulder pain in the overhand or throwing athlete. The relationship of anterior instability and rotator cuff impingement. *Orthop Rev* 18: 963-975, 1989
7. Kibler WB: Specificity and sensitivity of the anterior slide test in throwing athletes with superior glenoid labral tears. *Arthroscopy* 11: 296-300, 1995
8. Kim SH, Ha KI, Ahn JH, et al: Biceps load test II: A clinical test for SLAP lesions of the shoulder. *Arthroscopy* 17: 160-164, 2001
9. Kim SH, Ha KI, Han KY: Biceps load test: A clinical test for superior labrum anterior and posterior lesions in shoulders with recurrent anterior dislocations. *Am J Sports Med* 27: 300-303, 1999
10. Levy AS, Lintner S, Kenter K, et al: Intra- and interobserver reproducibility of the shoulder laxity examination. *Am J Sports Med* 27: 460-463, 1999
11. Liu SH, Henry MH, Nuccion SL: A prospective evaluation of a new physical examination in predicting glenoid labral tears. *Am J Sports Med* 24: 721-725, 1996
12. Mimori K, Muneta T, Nakagawa T, et al: A new pain provocation test for superior labral tears of the shoulder. *Am J Sports Med* 27: 137-142, 1999
13. Neer CS II, Foster CR: Inferior capsular shift for involuntary inferior and multidirectional instability of the shoulder. A preliminary report. *J Bone Joint Surg* 62A: 897-908, 1980
14. O'Brien SJ, Pagnani MJ, Fealy S, et al: The active compression test: A new and effective test for diagnosing labral tears and acromioclavicular joint abnormality. *Am J Sports Med* 26: 610-613, 1998
15. Rowe CR, Zarins B: Recurrent transient subluxation of the shoulder. *J Bone Joint Surg* 63A: 863-872, 1981
16. Silliman JF, Hawkins RJ: Classification and physical diagnosis of instability of the shoulder. *Clin Orthop* 291: 7-19, 1993
17. Snyder SJ, Karzel RP, Del Pizzo W, et al: SLAP lesions of the shoulder. *Arthroscopy* 6: 274-279, 1990
18. Speer KP, Hannafin JA, Altchek DW, et al: An evaluation of the shoulder relocation test. *Am J Sports Med* 22: 177-183, 1994